

BLOODPOOLAGENTS

CLINICAL EXAMPLES

**Pre-operative work-up
with Gadofosveset**

Pre-operative work-up with Gadofosveset

Clinical details

68-year-old man with symptomatic abdominal aortic aneurysm (AAA) primarily referred for peripheral MRA.

Extended field-of-view imaging using Gadofosveset: two indications – one single injection.

MR Equipment		
Coil(s)	Q-Body + Synergy-Body (Lower legs)	
MR Sequence Parameters	Dynamic	Steady State
Sequence	3D FFE T1	3D FFE T1
Repetition Time (ms)	2.70 / 2.80 / 4.80 (shortest)	4.80 / 4.90 / 5.8 (shortest)
Echo Time (ms)	0.89 / 0.94 / 1.36 (shortest)	1.42 / 1.44 / 1.68 (shortest)
Flip Angle (°)	25	25
Bandwidth (Hz/Pixel)	658 / 658 / 217	217 / 217 / 217
Slice Thickness (mm)	1.60 / 1.50 / 1.10	1.50 / 0.99 / 0.49
Number of Slices	65 / 60 / 80	90 / 95 / 170
FOV (mm)	451	451
Phase Field of View (%)	75	75
Acquisition Matrix (Pixel)	384 x 285 / 336 x 252 / 400 x 300	400 x 300 / 416 x 312 / 464 x 348
Resolution (mm3)	M: 1.48 x 2.33 x 3.40	M: 1.13 x 1.48 x 3.00
M: measured	R: 1.04 x 1.04 x 1.60	R: 0.88 x 0.88 x 1.50 AI
R: reconstructed	M: 1.34 x 2.11 x 3.00	M: 1.08 x 1.42 x 1.98
AI: Aorto-Iliac	R: 0.88 x 0.88 x 1.50	R: 0.88 x 0.88 x 0.99 UL
UL: Upper Leg	M: 1.13 x 1.77 x 2.20	M: 0.97 x 0.97 x 0.98
LL: Lower Leg	R: 0.88 x 0.88 x 1.10	R: 0.52 x 0.52 x 0.49 LL
Image Matrix (Pixel)	512 x 512	512 x 512
Acquisition Time (s)	12.60 / 13.40 / 35.90	100 / 111 / 174
Fat Saturation (yes/no)	no	no
Contrast Agent Application	Dynamic	
Test Bolus Contrast Media	Gadofosveset	
Application Type	fluroscopic triggering!	
MR Angiography		
Application Type	automated	
Volume Gadofosveset (ml)	10	
Flow Rate (ml/s)	1.20	
NaCl		
Application Type	automated	
Volume (ml)	30	
Flow Rate (ml/s)	0.60	

Authors:

PD Dr. med. Winfried A. Willinek, Dr. med. Dariusch R. Hadizadeh
 Universitätsklinik Bonn, Department of Radiology

Pre-operative work-up with Gadofosveset

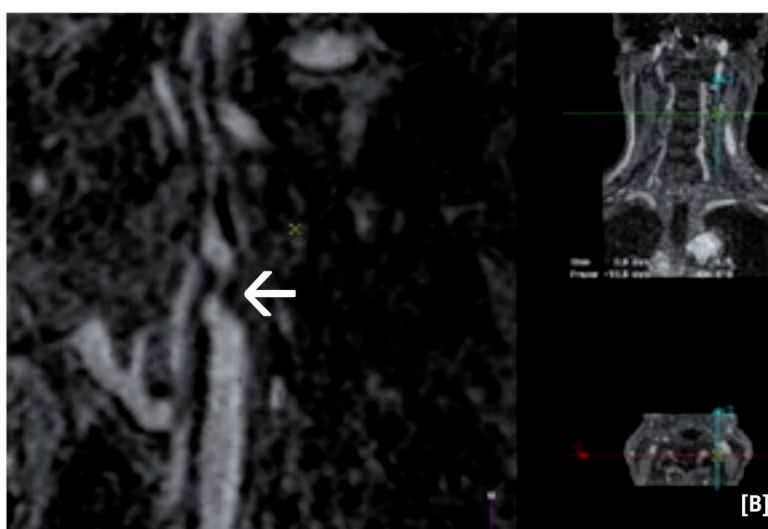
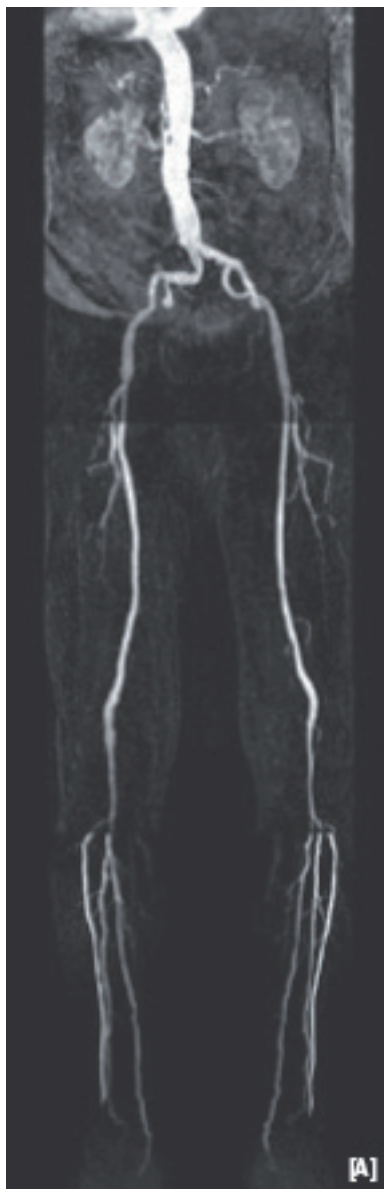
MR Equipment 2		
Coil(s)	Syn-Head/Neck coil	
MR Sequence Parameters	Dynamic	Steady State
Sequence	n/a	3D FFE T1
Repetition Time (ms)	n/a	4.70
Echo Time (ms)	n/a	1.56
Flip Angle (°)	n/a	40
Bandwidth (Hz/Pixel)	n/a	434
Slice Thickness (mm)	n/a	0.50
Number of Slices	n/a	130
FOV (mm)	n/a	350
Phase Field of View (%)	n/a	50
Acquisition Matrix (Pixel)	n/a	400 x 300 / 416 x 312 / 464 x 348
Resolution (mm ²)	n/a	G:0.81x0.81x1.00 BR:0.68x0.68x0.50
Image Matrix (Pixel)	n/a	512 x 512
Acquisition Time (s)	n/a	67
Fat Saturation (yes/no)	n/a	no

Authors:

PD Dr. med. Winfried A. Willinek, Dr. med. Dariusch R. Hadizadeh
Universitätsklinik Bonn, Department of Radiology

Summary of findings

Patient with symptomatic AAA referred for peripheral MRA. The high grade stenosis of the left ICA was confirmed by 64-MSCTA and the patient was discharged after successful thrombendarterectomy and aneurysm repair.



Description of images

After first-pass MRA of the abdomen and lower extremities, an ultra-sonographically suspected left ICA stenosis is confirmed by the 0.66 mm isotropic resolution steady-state MRA with Gadofosveset (arrow). This approach facilitates the pre-operative work-up of patients with systemic vascular disease without the need of a second contrast injection or a separate MR examination.

Authors:

PD Dr. med. Winfried A. Willinek, Dr. med. Dariusch R. Hadizadeh
Universitätsklinik Bonn, Department of Radiology