

MRA of Renal Arteries

Clinical History

This patient was a 77-year-old Caucasian male, bodyweight 87 kg, with a past medical history of hypertension, renal hypertension, occasional angina, myocardial infarction, status post-coronary artery bypass grafting, diabetes, constipation, prostate surgery, gout and bilateral carotid artery stenosis. He was taking Diovan®, verapamil, aspirin, nitropatch, hydrochlorothiazide, Glucophage® and indomethacin.

MR Imaging

MR imaging was carried out in 2002 on a Siemens 1.5 T whole-body scanner. Time-of-flight MR angiography was performed (data not shown). The resulting TOF MR angiogram, acquired with the best standard sequence available to the institution, revealed indications of renal artery stenosis. However, it was not possible to make a detailed and reliable diagnosis. In addition, dynamic and steady-state MR angiography following intravenous injection of gadofosveset were performed.

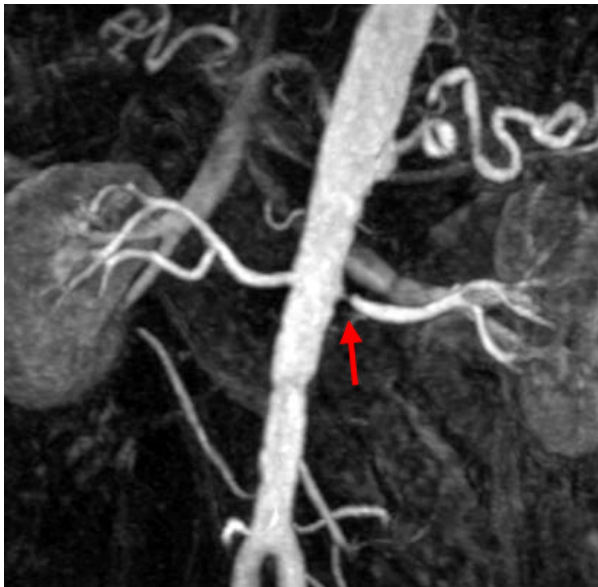

Fig. 1. Dynamic 3D gradient echo MR angiography (TE 1.9, TR 6.6, NEX 1, flip angle 25°, slice thickness 1.3 mm, field of view 320 mm with a 75 % phase resolution) was performed 30 seconds after i.v. bolus injection of the blood pool agent.

Comments on Fig. 1

This early-phase dynamic contrast-enhanced MR angiogram reveals clear evidence of significant stenosis of the left renal artery (red arrow). There is some irregularity in the wall of the abdominal aorta, indicating generalized atherosclerosis.

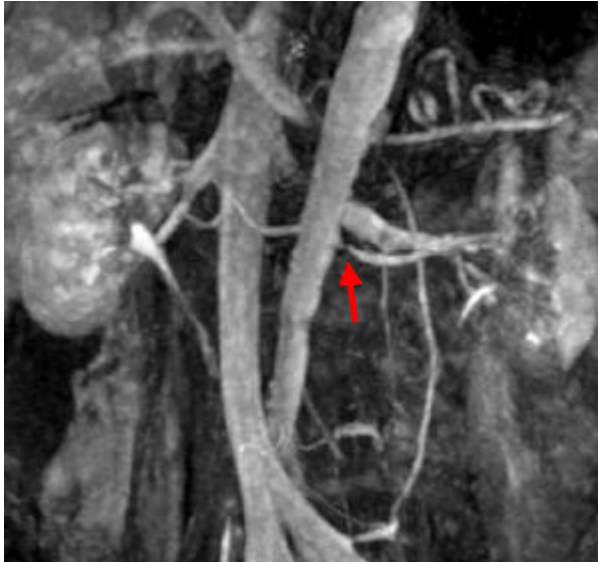


Fig. 2. The figure shows a coronal MIP image obtained with steady-state 3D gradient echo MR angiography (TE 1.9, TR 6.6, NEX 1, flip angle 20°, slice thickness 1.3 mm, field of view 320 mm with 75 % phase resolution), which was commenced 2 minutes 31 seconds after the start of the dynamic sequence with the blood pool agent.

Comments on Fig. 2

This steady-state MR angiogram shows significant stenosis of the left renal artery and regular opacification of the venous system. This image demonstrates the imaging potential of blood pool agents - even at a later time point (e.g. if the bolus is missed due to technical or patient-related problems). It also demonstrates the potential for imaging the venous system.

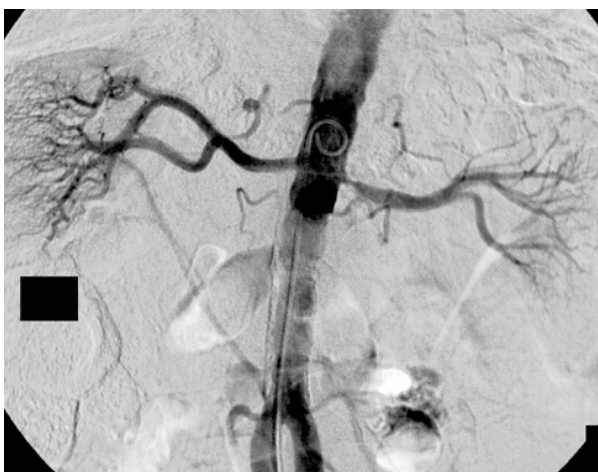

Fig. 3. Conventional catheter-based digital subtraction angiography establishes the diagnosis of significant stenosis of the left renal artery.

MR Diagnosis : Significant left-sided renal artery stenosis.